Physical Therapy in Sport 15 (2014) 3–14

Contents lists available at ScienceDirect

Physical Therapy in Sport

journal homepage: www.elsevier.com/ptsp

Masterclass

New concepts in restoring shoulder elevation in a stiff and painful shoulder patient

Robert Donatelli [a,*], R.M. Ruivo [b], Michael Thurner [c], Mahmoud Ibrahim Ibrahim [d]

[a] Outreach Sports Programs Physiotherapy Associates, 5920 South Rainbow Blvd Suite One, Las Vegas, NV 89118, USA
[b] Faculdade de Motricidade Humana, Universidade de Lisboa, Portugal
[c] Physiotherapy Associates, Las Vegas, NV, USA
[d] Department of Orthopedic & Sports Physical Therapy, Cairo University, Cairo, Egypt

ARTICLE INFO

Article history:
Received 1 March 2013
Received in revised form
31 October 2013
Accepted 1 November 2013

Keywords:
Joint mobilization
Manual therapy
Shoulder

ABSTRACT

The treatment and evaluation of a stiff and painful shoulder, characteristic of adhesive capsulitis and "frozen" shoulders, is a dilemma for orthopedic rehabilitation specialists. A stiff and painful shoulder is all-inclusive of Adhesive capsulitis and Frozen Shoulder diagnoses. Adhesive capsulitis and frozen shoulder will be referred to as a stiff and painful shoulder, throughout this paper.

Shoulder motion occurs in multiple planes of movement. Loss of shoulder mobility can result in significant functional impairment. The traditional treatment approach to restore shoulder mobility emphasizes mobilization of the shoulder overhead. Forced elevation in a stiff and painful shoulder can be painful and potentially destructive to the glenohumeral joint. This manuscript will introduce a new biomechanical approach to evaluate and treat patients with stiff and painful shoulders.

© 2013 Elsevier Ltd. All rights reserved.

1. Introduction

Shoulder elevation is an evidently important functional movement required in activities of daily living (ADL's) and athletic activities involving reaching movements away from or across body, reaching overhead and/or throwing in sport. Activities of daily living may include but certainly not limited to dressing, bathing, overhead reaching, and don/doffing bra or clothing. Athletic activities include most sports such as swimming, baseball, football, basketball, tennis, and handball. A stiff and painful shoulder occurs when a patient loses critical motion in the shoulder and it becomes difficult and painful to move the joint in all of the planes of movement (Dudkiewicz, Oran, Salai, Palti, & Pritsch, 2004; Lubiecki & Carr, 2007).

The pain and restricted range of motion are characteristics of the adhesive capsulitis and frozen shoulder diagnoses. Adhesive capsulitis is a pathologic condition resulting from inflammation of the joint capsule and synovium followed by fibrosis, scarring and contracture of the capsuloligamentous complex. The capsuloligamentous changes result in global loss of both passive and active range of motion (ROM) of the glenohumeral joint. In most patients with a painful and stiff shoulder external rotation is the most restricted physiologic movement (Neviaser & Hannafin, 2010; Soren & Fetto, 1996; Uhthoff & Boileau, 2007). Abnormal shoulder kinematics may present with decreased scapular posterior tipping and upward rotation during arm elevation (Yang, Jan, Chang, & Lin, 2012). As the patient repetitively moves the shoulder, scarring and/or contractures typically worsen, resulting in further decrease in range of motion (Dias, Cutts, & Massoud, 2005; Earley & Shannon, 2006).

The incidence of shoulder adhesive capsulitis has been estimated to be from 3% to 6% in the general population (Blanchard, Barr, & Cerisola, 2010; Neviaser & Hannafin, 2010). It is reported in the literature that shoulder adhesive capsulitis is more frequent in women aged between 40 and 60 years (Wong & Tan, 2010) and in about 20–30% of cases this condition is bilateral (Zuckerman & Rokito, 2011). Patients suffering from shoulder adhesive capsulitis face months to years of progressive pain, stiffness and disability (Green, Buchbinder, & Hetrick, 2003; Jewell, Riddle, & Thacker, 2009).

Adhesive capsulitis is a medical diagnosis used by the International Classification of Diseases (ICD) and can be divided into two categories: primary, in which there are no obvious causes, and secondary, where a cause is identified (from history, clinical examination and radiographic appearances). Those with diabetes, prolonged shoulder immobility (trauma, overuse injuries or surgery) or systemic diseases (hyperthyroidism, hypothyroidism, cardiovascular disease or Parkinson's disease) are at a higher risk (Wong & Tan, 2010).

* Corresponding author. Tel.: +1 404 680 7988 (mobile), +1 702 248 7903.
E-mail addresses: Bobbyd1950@gmail.com (R. Donatelli), Rodrigo.Ruivo@netcabo.pt (R.M. Ruivo), michaelsthurner@yahoo.com (M. Thurner), msrt78@aol.com, imahmoud@nova.edu (M.I. Ibrahim).

1466-853X/$ – see front matter © 2013 Elsevier Ltd. All rights reserved.
http://dx.doi.org/10.1016/j.ptsp.2013.11.001

Various researchers have described four stages of primary or secondary adhesive capsulitis, based on history, physical examination, and arthroscopic findings (Neviaser & Hannafin, 2010). In the first two stages, pain is characteristic of the chief complaint, and in the third and fourth stages stiffness is the predominant problem.

Stiffness is the major problem (Neviaser & Hannafin, 2010). The hallmark of stage 3 and 4 is restricted ROM or stiffness in the shoulder joint, exemplified by limited shoulder elevation activities (Neviaser & Hannafin, 2010). Unfortunately most of the patients that are referred to physical therapy with a diagnosis of adhesive capsulitis, frozen shoulder or a stiff and painful shoulder are not diagnosed as to what stage they are in.

Therefore, it is important in all stages that the clinician evaluates for impairments in the capsuloligamentous complex and musculotendinous structures surrounding the shoulder complex when the patient presents with shoulder pain and limited mobility. The loss of passive motion in multiple planes, especially external rotation in the adducted position, at 30°, 45° and 90° of abduction, are significant findings that can be used to guide the treatment plan (Kelly et al., 2013). Differential soft tissue diagnosis of a stiff and painful shoulder should be made by the clinician, after determining the soft tissues or periarticular structures that are restricting the shoulder mobility. Therefore, the stiff and painful shoulder could be from a fibrosis within the capsule, contracture of a tendon or an inflamed synovium and/or the capsuloligamentous complex.

Interventions for patients with adhesive capsulitis remain controversial and poorly understood (Bal, Eksioglu, Gulec, Aydog, Gurcay, & Cakci, 2008; Bergman et al., 2004; Buchbinder et al., 2007; Hay, Thomas, Paterson, Dziedzic, & Croft, 2003; Neviaser & Hannafin, 2010). Many studies have been reported in the orthopedic, physical therapy, and rheumatology literature in the past 40 years (Baums, Spahn, Nozaki, Steckel, Schultz, & Klinger, 2006; Carette et al., 2003; Diercks & Stevens, 2004; Neviaser & Hannafin, 2010). Treatment options documented in the literature include, physical therapy treatment, nonsteroidal anti-inflammatory medications, oral corticosteroid medications, intra-articular hydrocortisone injections, distension arthrography, closed manipulation, manipulation under anesthesia, open surgical release, and more recently, arthroscopic capsular release (Castellarin et al., 2004; Farrell, Sperling, & Cofield, 2005; Hannafin & Chiaia, 2000; Kivimäki et al., 2007). However, it is difficult to compare and apply the results clinically due to the lack of documentation as to the specificity of stage in which the adhesive capsulitis is referenced (Hay et al., 2003; Neviaser & Hannafin, 2010).

A time-honored technique in shoulder therapy is the low-load prolonged stretch and static progressive stretch (Bonutti, Hotz, Gray, Cremens, Leo, & Beyers, 1998). This technique requires placing the scarred or contracted tissue under stain at the end range of available motion with the intent to incrementally increase the mobility of the glenohumeral joint with the expectation of plastic remodeling of the periarticular connective tissues to ultimately improve active and passive range of motion of the shoulder (Bonutti, McGrath, Ulrich, McKenzie, Seyler, & Mont, 2008; Mclure, Blackburn, & Dusold, 1994). Ideally, splints utilizing a static progressive stretch allow the patient to control the degree of stretch, to minimize the risk of overstretching and damaging the tissue (Bonutti et al., 1998). Such splints have shown success when used to treat the shoulder (Dempsey, Mills, Karsch, & Branch, 2011) and other joints (Bonutti et al., 2008; Doornberg, Ring, & Jupiter, 2006; Ulrich et al., 2010). Table 1

In treating joint stiffness, we believe clinicians and physiotherapists should adjust the amount of tensile stress applied to the periarticular tissues until a therapeutic result (increased ROM) is achieved. An insufficient amount of stress will have no therapeutic effect, where as an excessive dose will produce complications such as pain and inflammation. Three factors should be considered when calculating the prescribed amount of force delivered to soft tissues: intensity, duration and frequency.

As seen in Table 1 Bonnuti, Windau, Ables, & Miller (1994), in his study reported motion gains with the use of 30 min sessions up to three times per day as tolerated. Dempsey et al., (2011) performed six 10 min-bouts of end range stretching, daily, whereas Ibrahim et al.

Table 1
Use of low load prolonged stretch in different studies.

Reference	Frequency	Duration	Intensity	Joint	Main conclusion
Ibrahim et al. (2012)	Once daily for the first week, twice daily during weeks 2 and 3, and three sessions per day in week 4	6 sets of 5 min stretches (30′ total each session)	The endpoint for passive abduction was considered the point at which the patient began to experience pain	Shoulder	Use of a static progressive stretch orthosis for patients with shoulder adhesive capsulities resulted in significantly better range of motion within 1 month of beginning treatment than physical therapy alone
Dempsey et al. (2011)	Daily	10 min-bouts of end range stretching	Uncomfortable but beneath the pain threshold	Shoulder	A total end range time maximizing rehabilitation protocol is a safe, effective treatment option for patients with frozen shoulder
Ulrich et al. (2010)	1 to 3 sessions daily for a mean of 10 weeks	30-min stretching protocol	Uncomfortable but beneath the pain threshold	Elbow	Consistent improvements in restoring range of motion can be achieved with short treatment times by using a device based on the principles of static progressive stretch and stress relaxation in patients with posttraumatic elbow contractures
Bonutti et al. (2008)	One treatment session per day for the first 5 days, and then increased the frequency as tolerated to a maximum of three sessions per day	30-min treatment session	Until they felt a gentle stretch.	Knee	An orthosis that utilizes the principles of static progressive stretch may be a successful treatment for improving the range of motion and satisfaction of patients who have knee contractures.
Dorneberg et al. (2006)	3 times a day	30′ in each direction (flexion and extension)	–	Elbow	Static progressive splinting can help gain additional motion when standard exercises seem stagnant or inadequate
Bonutti et al. (1994)	3 times per day as tolerated	30′ each session	Uncomfortable but beneath the pain threshold	Elbow	Improvements in restoring elbow range of motion

(2012) advised for six sets of 5 min stretches (30 min therapy session). In addition to Ibrahim et al. (2012) other studies, recommended 30-min treatment protocol, working up to 3 sessions daily (Donatelli, Wilkes, Hall, & Cole, 2006; Ulrich et al., 2010). Intensity, which is the amount of force applied, is usually limited by the patient's pain tolerance.

Multimodal care, including mobilization, shoulder orthoses, and stretching and strengthening exercises, appears to be beneficial for pain relief and functional improvement, but the evidence is limited (Geraets et al., 2005; Hand, Clipsham, Rees, & Carr, 2008; Levine, Kashyap, Bak, Ahmad, Blaine, & Bigliani, 2007; Michlovitz, Harris, & Watkins, 2004; Smidt et al., 2005). In what concerns manual therapy there are some studies that demonstrates important benefits (Yang, Chang, Chen, Wang, & Lin, 2007), such as improved range of motion, however, and the gains have been reported to be temporary. There is limited data to support one form of manual therapy versus another (Neviaser & Hannafin, 2010; Vermeulen, Rozing, Obermann, le Cessie, & Vliet Vlieland, 2006).

It is our experience that very often, physical therapy interventions cause severe pain and possible damage to subacromial structures when passive ROM into elevation is used as a treatment approach. Restoring elevation in a time-efficient manner remains a challenging problem. Forcing the shoulder into elevation, causing pain, may increase inflammation, resulting in the formation of more scar tissue. Therefore, traditional methods of restoring shoulder elevation by forcing the stiff and painful shoulder overhead in the rehabilitation process need to consider the joint biomechanics and patient response.

This article offers a new treatment approach for stiff and painful shoulder patients, which include adhesive capsulitis and/or Frozen Shoulder diagnoses. The treatment approach is based on a greater understanding of the normal motion of the shoulder during humeral elevation. The literature is devoid of any studies that promote rotation before elevation in order to avoid increasing the patients' pain which may cause more inflammation. We also introduce a novel concept of passive rotation testing in the assessment of patients with shoulder motion abnormalities. The interpretation of rotation limits that may help to guide the clinician in determining the direction and focus of the rehabilitation program.

2. Shoulder mechanics

The shoulder consists of two force couples; one at the glenohumeral (GH) joint and the other is at the scapulothoracic articulation (Neumann, 2009, pp. 122–124; Nordin & Frankel, 2001). A force couple is defined as two equal but oppositely directed forces acting simultaneously on opposite sides of an axis that generates rotation. In mechanics, a couple is a system of forces that results in a moment without a resultant force, to create a rotation without translation (Norkin & Levangie, 1992, pp. 230–232).

Ludewig and Reynolds (2009) observed that the component movements of shoulder motion during humeral elevation 30° anterior to the frontal plane (plane of the scapula (POS)) included clavicular elevation and posterior axial rotation; scapular internal rotation, upward rotation, and posterior tilting relative to the clavicle; and GH elevation and external rotation. Overall shoulder motion consists of substantial angular rotations of the humerus, scapula and clavicle enabling the multiple-joint interaction of the glenohumeral, acromioclavicular and scapulo-thoracic articulations, required to elevate the arm overhead (Neumann, 2009, pp. 122–124; Nordin & Frankel, 2001).

A scapular force couple is produced by the trapezius and serratus anterior during upward rotation of the scapula with arm elevation. Though the trapezius and serratus anterior are producing linear opposing forces, there is no linear translation of the scapula (Neumann, 2009, pp. 122–124). Upward rotation of the scapula assists arm elevation.

The GH force couple is a modified force couple secondary to the fact that the two forces involved are not opposite to one another. The deltoid produces a superior force, while the subscapularis and infraspinatus/teres minor produce a compressive and inferior force (Neumann, 2009, pp. 122–124). Although the forces at the GH joint are not equal but oppositely directed forces, the combined compressive forces of the subscapularis and infraspinatus/teres minor pull the head into the glenoid, counteracting the superior shear force of the deltoid muscle. Because of this compressive force and the geometry of the GH joint (ball and socket), the overall effect is rotation of the humerus with a very small superior and inferior linear translation of the humeral head.

Rotation of the humeral head must take place with any movement of the humerus. Though the movements of the humerus in elevation can be described as moving through the sagittal and frontal planes of motion, the humerus is actually moving through an arc of motion, with a fixed proximal segment (humeral head)

Fig. 1. Passive external rotation of the GH joint in the frontal plane at zero degrees of abduction, the subscapularis muscle is the most important stabilizer of the GH joint.

that is rotating on a base (glenoid fossa) (Neumann, 2009, pp. 122–124). Therefore, evaluation and treatment should be consistent with the biomechanics of the shoulder movements of rotation.

In the context of restoring shoulder motion the cervicothoracic contribution to humeral elevation needs to be recognized. For example a forward head posture has been associated with an increase in the thoracic kyphosis angle which may result in a forward shoulder posture. The forward posture of the shoulder may cause the scapula to be in a relatively more elevation, protraction, an anterior tilt and a downwardly rotated posture (Kendall, McCreary, & Provance, 1993) The changes noted above lead to a loss of glenohumeral flexion and abduction (Kibler, 1998). Also Cook and Ludewig (1996) evaluated the effect of cervical position on scapula orientation on 25 healthy subjects. The results suggested that increased cervical flexion prevented upward rotation and posterior tilt of the scapula. The researchers postulated that cervical flexion generated tension in levator scapulae which impeded optimal scapular kinematics.

3. Clinical importance of GH rotation

Many studies justify the importance of restoring passive external rotation of the GH joint and explore why there could be a simultaneous effect on active abduction in the plane of the scapula (POS). Mao, Jaw, and Cheng (1997) demonstrated that restoring passive external rotation resulted in increased flexibility of the GH capsule, which in turn helps to restore shoulder movements in all planes. Increased extensibility of the GH capsule may be important in restoring active elevation. In a cadaver study, other investigators found that shortening of the anterior GH capsule seven mm resulted in loss of external rotation. Cyriax (1975) reported that the movement with the greatest percentage of limitation in patients with adhesive capsulitis was passive external rotation, followed by elevation in the frontal plane (abduction). Cyriax (1975) and Browne, Hoffmeyer, Tanaka, and Morrey (1990) demonstrated that external rotation is required during arm elevation in any plane anterior to the scapula and that internal rotation is required during arm elevation in any plane posterior to the POS.

Fig. 2. Passive External rotation at 45° of abduction in the frontal plane – The most stabilizing structures - portion of the subscapularis and the middle glenohumeral ligament are the most stabilizing mechanisms to the anterior capsule.

Fig. 3. Passive external rotation at 90° of abduction in the frontal plane. The most stabilizing structure is the inferior glenohumeral ligamentous complex.

Brems (1994) discussed the importance of restoring passive GH external rotation ROM. It has been recognized that an "obligatory" axial external rotation of the humerus is necessary to clear the greater tuberosity from the acromial arch. Ludewig and Reynolds (2009) and Vermeulen, Stokdijk, Eilers, Meskers, Rozing, and Vliet Vlieland (2002) reported that the loss of GH joint mobility in adhesive capsulitis is likely due to capsular adhesions, which limit external rotation of the humeral head. Based on the evidence noted above (Browne et al., 1990; Mao et al., 1997; Pearsall & Speer, 1998; Rizk, Christopher, Pinals, Higgins, & Frix, 1983; Vermeulen et al., 2002), restoring passive external rotation to the GH joint is a more effective method of increasing active elevation of the GH joint than forcing the shoulder into passive and/or active elevation.

4. Clinical importance of scapula rotation

Konda, Yanai, and Sakurai (2010) demonstrated that a coordination of the scapular and GH rotations contributes to the attainment of peak shoulder external rotation exhibited at the end of the cocking phase in the tennis serve. As noted above, Ludewig and Reynolds (2009) reported that during arm elevation overhead, the scapula is rotating upward, and tilting posterior relative to the clavicle at the acromioclavicular (AC) joint. There is strong evidence that changes in the above scapula kinematics in patients with impingement or rotator cuff symptoms (Hébert, Moffet, McFadyen, & Dionne, 2002; Laudner, Myers, Pasquale, Bradley, & Lephart, 2006; McClure, Michener, & Karduna, 2006). An increase in upward scapula rotation and posterior tilt is recorded in asymptomatic individuals when compared to symptomatic subjects. Su, Johnson, Gracely, and Karduna (2004) reported that scapula upward rotation measurements in patients with impingement decreased after swim training at 45°, 90°, and 135° of humeral elevation. The greatest decrease in scapular upward rotation was at 135° of humeral elevation. This finding suggests that the scapular kinematics of swimmers may change with fatigue of the scapula rotator muscles, which may result in shoulder impingement syndrome (Su et al., 2004).

Although there are many muscles that assist with scapular motion, the three muscles that are traditionally attributed as upward rotators are the upper trapezius, lower trapezius, and serratus anterior (Solem-Bertoft, Thuomas, & Westerberg, 1993). The use of magnetic resonance imaging in an in vivo setting demonstrated that changes in scapular position can influence clearance in the subacromial space (Solem-Bertoft et al., 1993).

5. Assessment of shoulder mobility

Assessing active and passive shoulder elevation allows the clinician to test for gross functional deficits only. It is difficult to make a differential soft-tissue diagnosis unless further testing is performed. Assessment of internal and external passive rotation of the GH joint allows the clinician to develop a more specific soft-tissue differential diagnosis. Directly measuring tissue behaviors in human subjects is seldom possible, so cadavers are often used as a model to examine questions regarding soft tissue response to loads (Borstad & Dashottar, 2011). Several cadaver studies have calculated the mechanical strain on soft-tissue structures surrounding the GH joint during passive rotation. Limiting the GH external rotation we can consider the coraco-humeral ligament (Izumi et al., 2011), the pectoralis major, the long head of the biceps (McGahan, Patel, Dickinson, Leasure, & Montgomery, 2013) and the subscapularis among others. Turkel, Panio, Marshall, and Girgis (1981) reported that during passive external rotation of the GH joint in the frontal plane at zero degrees of abduction, the subscapularis muscle is the most important stabilizer of the GH joint (Fig. 1). At 45° of abduction in the frontal plane, a portion of the subscapularis and the middle GH ligament are the most stabilizing mechanisms to the anterior capsule (Fig. 2). At 90° of abduction, the most stabilizing structure of the anterior capsule is the inferior GH ligamentous complex (Fig. 3) (Turkel et al., 1981).

Muraki, Aoki, Uchiyama, Takasaki, Murakami, and Miyamoto (2007) studied the strain on the three bellies of the subscapularis muscle during passive external rotation in several positions. Their results demonstrated that passive external rotation in the POS (30° anterior to the frontal plane) (Fig. 4) created a large muscle strain on the lower fiber group, and simultaneously the study reported a positive muscle strain on the upper and middle fiber groups. In external rotation with 0° of elevation only a small amount of positive strain was observed in the upper and middle fibers groups (Muraki et al., 2007).

The referenced dissection studies can be useful for clinical application in the assessment of passive rotation ROM restrictions. The assessment may help guide the clinician's treatment approach providing insight of the specificity of soft tissue restrictions.

Izumi, Aoki, Muraki, Hidaka, and Miyamoto (2008) demonstrated in a dissection study that various positions with the GH joint passively rotated internally place a strain on different portions of the posterior capsule. Based on their results, the first position of the shoulder was rotated internally at 30° of abduction and in the POS. This position was determined to provide a significant strain to

Fig. 4. Passive external rotation at 30° of glenohumeral elevation in the plane of the scapula (POS) provides a strain to upper, middle and lower fibers of the subscapularis.

the upper and middle parts of the posterior capsule (Fig. 5). The second position was at 30° of shoulder abduction and extension with internal rotation; this provided a significant strain to the lower fibers of the posterior capsule (Fig. 6) (Izumi et al., 2008). In another study, 90° of flexion and horizontal adduction with internal rotation provided good general strain of the posterior capsule (Fig. 7) (Tyler, Roy, Nicholas, & Gleim, 1999).

Borstad and Dashottar (2011) compared 5 simulated clinical tests of posterior shoulder tightness using eight fresh frozen cadaver extremities. The study determined that internal rotation at 60° of flexion and 40° of flexion produced greater strain in the middle region of the experimentally contracted posterior glenohumeral joint capsule (Borstad & Dashottar, 2011).

6. Treatment

Remodeling of the connective tissue involves a subtle rearrangement of the collagen and crosslinks within the tissue

Fig. 5. Passive internally rotated at 30^0 of abduction and in the plane of the scapula. This position provides a significant strain to the upper and middle fibers of the posterior capsule.

Fig. 6. Passive internal rotation at 30° of shoulder abduction and extension. This produces a significant strain to the lower fibers of the posterior capsule.

(Lundberg, 1970; Nordin & Frankel, 2001; Ozaki, Nakagawa, Sakurai, & Tamai, 1989). A permanent increase in pain-free ROM is the goal of treatment for patients with stiff and painful shoulders. The rehabilitation specialist should attempt to apply end-range tensile stress to restricting periarticular structures. It has been shown that force applied to the tissue, accompanied by a progressively increased load, will produce a plastic deformation (Light, Nuzik, Personius, & Barstrom, 1984; Warren, Lehmann, & Koblanski, 1971). Vermeulen et al. (2000) reported a case report in which end-range mobilization techniques were effective in restoring permanent changes in passive and active overhead movements in patients with adhesive capsulitis.

McClure et al. (2006) suggested that to make improvements in the mobility of a stiff shoulder, treatment should be geared toward applying tension to the capsule, extracapsular ligaments, and tendons of the rotator cuff, in an effort to elongate the restricting tissues. Low-load stretches had been advocated earlier as an effective technique to increase extensibility of the GH capsule (McClure & Flowers, 1992). Bonutti et al. (2008) demonstrated a similar concept termed

Fig. 7. Passive internal rotation at 90° of flexion provides a good general strain of the posterior capsule.

static progressive stretch, which involves incremental application of stress-relaxation loading to restricted soft tissues of the capsule, ligaments, and tendons. It can also be addressed that the use of low load prolonged stretch can be accompanied by thermotherapy (Light et al.. (1984), with good results, allowing more permanent changes ROM. It is believed the heat will facilitate muscle relaxation (Ibrahim et al., 2012).

Also the use of home mechanical therapy devices can be really useful and helps maximize the total end range time. For example, in the case of a patient with a severely stiff adhesive capsulitis shoulder, it is important to provide stretching to the capsular structure on a daily basis. Some home-rotational devices has been created, such as the one develop by Joint Active Systems (JAS)(Effingham, IL), to increase external and internal rotation at the GH joint using the static progressive stretch technique. These devices should not be used in shoulders that have any degree of heterotopic ossification or true bony blocks to motion. The brace is usually very easy to put on a pain and stiff shoulder because there is no need to raise the arm past 10–20° of abduction, The adhesive straps make it easy to secure it to the trunk.

According to Ibrahim et al. (2012), the progressive stretch orthosis devices creates a safe stress-relaxation load that creates plastic deformation within hours (Fig. 8). For example, the shoulder JAS device provides an external rotation or internal rotation stretch from a range of neutral to 90° of abduction in the scapular plane.

This particular rotational device has already proved to be effective in the gaining of range of motion in patients with shoulder adhesive capsulities (Ibrahim et al., 2012). In this study the patients upper extremity was placed in orthosis and secured with straps, with the amount of stretch controlled by the patient using a knob to move the shoulder into rotation until a stretch is felt. The stretch position was held for a six sets of 5 min stretches (30 min therapy session). The device was worn once daily for a 30 min session for the first week, twice daily for 30 min each during weeks 2 and 3, and three 30-min sessions per day in week 4.

Other home mechanical devices with time approaches also proved to be effective for the shoulder capsulitis such as performing six 10 min-bouts of end range stretching, daily (Dempsey et al., 2011). In this study the use of the low load prolonged stretch with the device was only used after the patients had failed 6 weeks of supervised conventional physical therapy. It must be emphasized that when using home-rotation devices, that can be self-applied patients users must be instructed to move the joint to the end range of motion, until they feel a stretch, but before they begin to experience pain.

In addition to the use of these home mechanical therapy devices and the low-load prolonged stretch therapy the intervention strategy for stiff and painful shoulders shoulder patients should include an individualized manual therapy and exercise treatment approach. The end results of the therapy should be focused on targeting the ROM improvement and the diminishing of pain.

7. Low-load stretch positional specificity

Treatment involving passive low-load stretch into external and internal rotation can be made more specific, based on the assessment of soft-tissue joint restrictions, as noted above.

1. Passive external rotation of the GH joint in the adducted position or at 0° of abduction in the POS provides strain to the lower and middle fibers of the subscapularis (Fig. 9).
2. Passive external rotation of the GH joint at 30° of abduction in the POS provides strain to the upper, middle, and lower fibers of the subscapularis (Fig. 10).
3. Passive external rotation of the GH joint at 45° of abduction stretches the subscapularis and middle GH ligament (Fig. 11).
4. Passive external rotation of the GH joint at 90° of abduction stretches the inferior ligament complex (Fig. 12).
5. Passive internal rotation of the GH joint at 30° of abduction in the POS provides stretch to the superior portion of the posterior capsule (Fig. 13).
6. Passive internal rotation of the GH joint at 30° of extension and internal rotation provides stretch to the inferior portion of the posterior capsule (Fig. 14).
7. Passive flexion and internal rotation of the GH joint at 90° of abduction provides general stretch to the posterior capsule (Fig. 15) (This position can be adjusted depending on pain and joint restrictions to 60° or 40°).

8. Research limitations

It must be emphasized conclusions extracted from the cadavers studies has some limitations. In the presented studies the shoulder

Fig. 8. JAS device home program – static progressive stretch into external rotation -

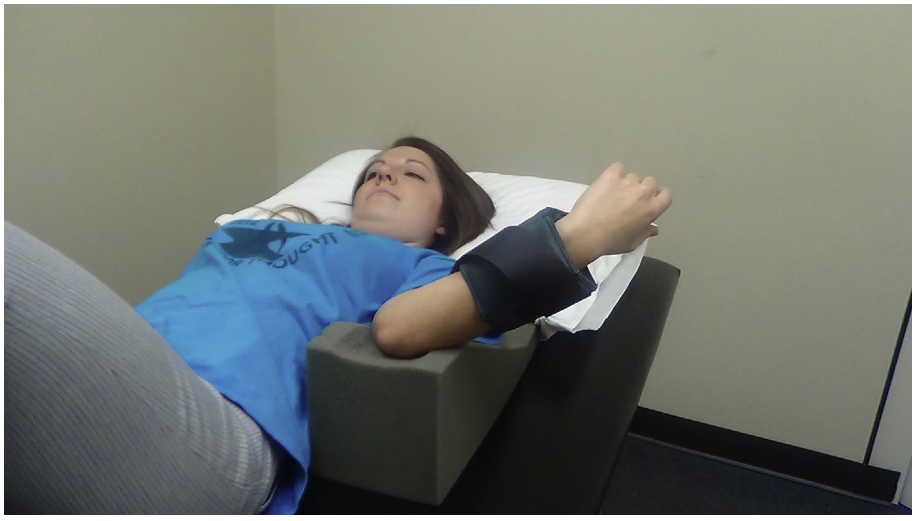

Fig. 9. Low load stretch into external rotation of the GH joint in the adducted position or zero degrees of abduction in plane of the scapula (POS) – tissue strain of the lower and middle fibers of the subscapularis.

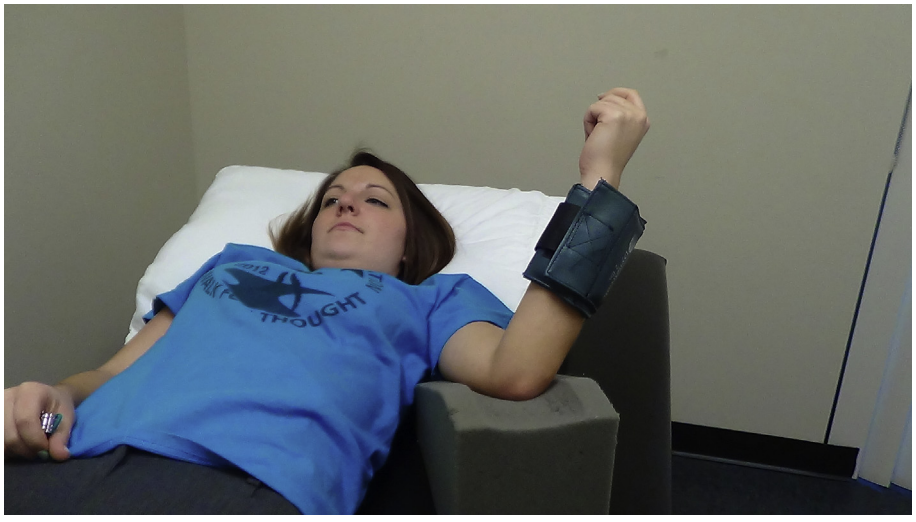

Fig. 10. Low load stretch into external rotation of the GH joint at 30° of abduction in the POS strain to the upper, middle and lower fibers of the subscapularis.

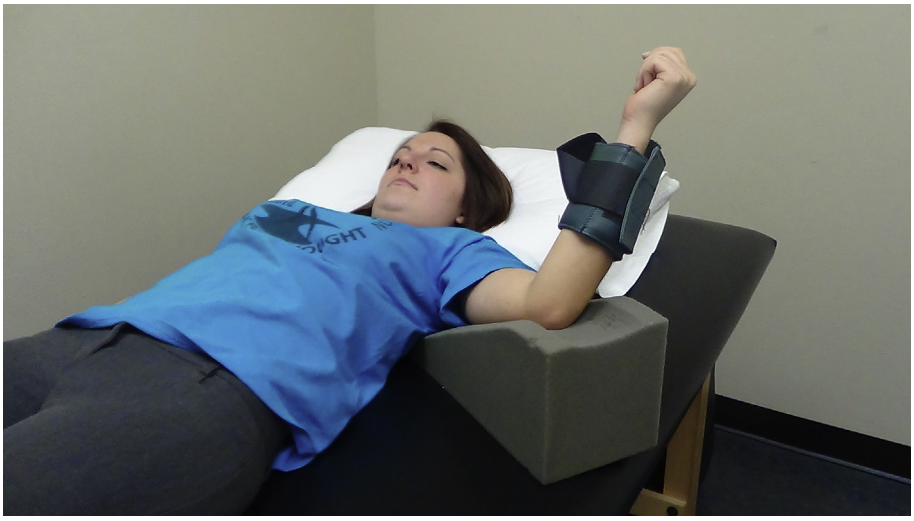

Fig. 11. Low load stretch into external rotation of the GH joint in 45° of abduction stretches in the POS, the subscapularis and middle glenohumeral ligament.

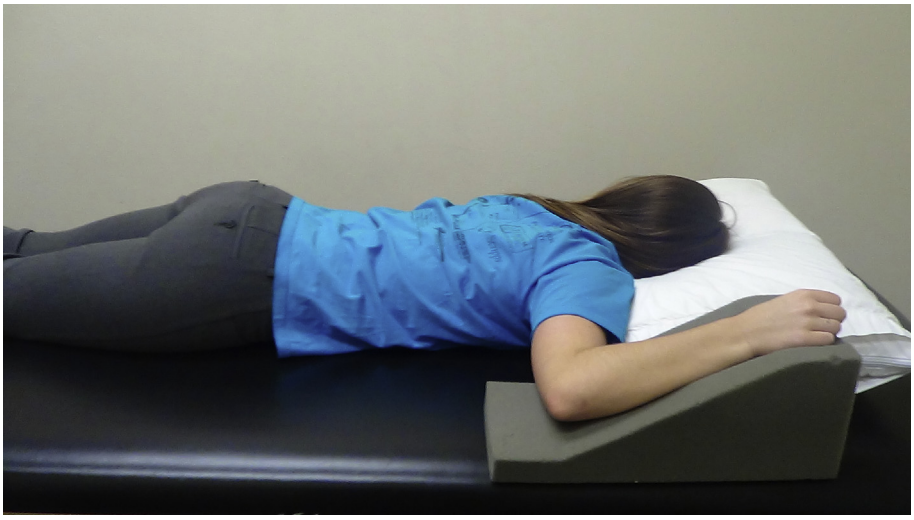

Fig. 12. Low load stretch into external rotation of the GH joint at 90° of abduction stretches the inferior ligament complex.

Fig. 13. Low load stretch into internal rotation of the GH joint at 30° of abduction and in the POS tissue provides a stretch to the superior portion of the posterior capsule.

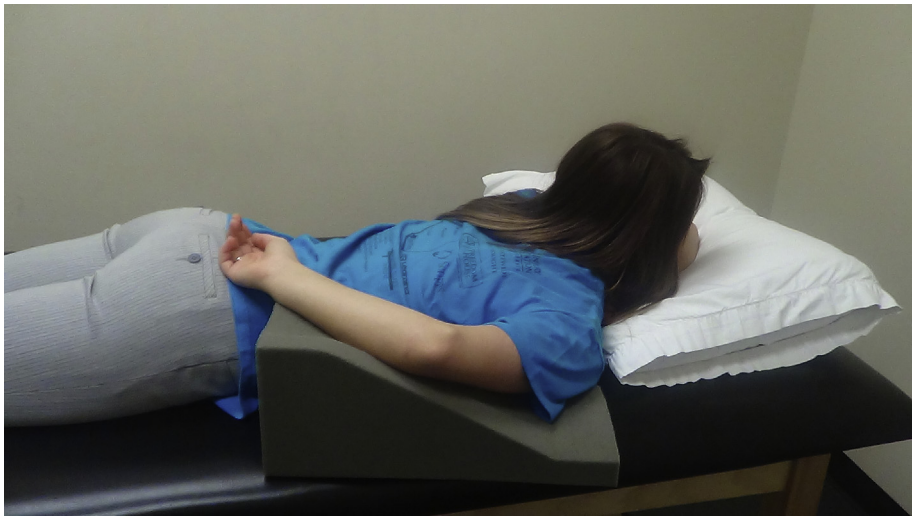

Fig. 14. Low load stretch into internal rotation of the GH joint at 30° of extension and internal rotation tissue provides a stretch the inferior portion of the posterior capsule.

Fig. 15. Low load stretch into internal rotation and 90° of Glenohumeral joint flexion provides a general stretch to the posterior capsule.

specimens were harvested from aged cadavers, the ROM and mechanical properties of the specimens might differ from those of specimens from younger people. Also, in Muraki study (2007), their findings may be slightly different from the in vivo studies because they did not consider the scapular position in the sagittal plane.

9. Summary

The shoulder is a complex network of force couples that interact simultaneously influencing multiple joint articulations allowing significant mobility in all planes of motion. Patient suffering from a 'stiff and painful' shoulder, characteristic of adhesive capsulitis, but not limited to this pathology may benefit from the assessment method and treatment approach suggested in this article. Research is needed in the assessment and treatment approaches to the stiff and painful shoulder patient. Pushing the shoulder into painful elevation ranges may cause greater periarticular tissue damage resulting in longer periods of disability and a reduction in the quality of life.

We have presented an alternative to forcing the shoulder into painful and restricted elevation ROM. A low-load prolonged stretch, within each patient's tolerance level, into various rotation restrictions may result in safe, effective and timely return to elevation range of motion. Several cadaver studies have demonstrated that internal and external rotation at different postures from 0° to 90° of elevation and flexion places specific strains on the capsule and musculature surrounding the GH joint. Testing rotation gives the clinician a more specific soft-tissue diagnosis regarding where the restrictions are within the periarticular tissues.

Ethical approval
None.

Funding
No funding.

Conflict of interest
There is no conflict of interest.

References

Bal, A., Eksioglu, E., Gulec, B., Aydog, E., Gurcay, E., & Cakci, A. (2008). Effectiveness of corticosteroid injection in adhesive capsulitis. *Clinical Rehabilitation, 22*(6), 503–512.

Baums, M. H., Spahn, G., Nozaki, M., Steckel, H., Schultz, W., & Klinger, H. M. (2006). Functional outcome and general health status in patients after arthroscopic release in adhesive capsulitis. *Knee Surgery, Sports Traumatology, Arthroscopy, 15*(5), 638–644.

Bergman, G. J., Winters, J. C., Groenier, K. H., Pool, J. J., Meyboom-de Jong, B., Postema, K., et al. (2004). Manipulative therapy in addition to usual medical care for patients with shoulder dysfunction and pain: a randomized, controlled trial. *Annals of Internal Medicine, 141*(6), 432–439.

Blanchard, V., Barr, S., & Cerisola, F. L. (2010). The effectiveness of corticosteroid injections compared with physiotherapeutic interventions for adhesive capsulitis: a systematic review. *Physiotherapy, 96*(2), 95–107.

Bonutti, P. M., Windau, J. E., Ables, B. A., & Miller, B. G. (1994). Static progressive stretch to reestablish elbow range of motion. *Clinical Orthopaedics and Related Research*, 128–134.

Bonutti, P., Hotz, M., Gray, T., Cremens, M., Leo, C., & Beyers, M. (1998). Joint contracture rehabilitation: static progressive stretch. *The Journal of Bone and Joint Surgery, 22*(1).

Bonutti, P. M., McGrath, M. S., Ulrich, S. D., McKenzie, S. A., Seyler, T. M., & Mont, M. A. (2008). Static progressive stretch for the treatment of knee stiffness. *Knee, 15*(4), 272–276.

Borstad, J. D., & Dashottar, A. (2011). Quantifying strain on posterior shoulder tissues during 5 stimulated clinical tests: a cadaver study. *The Journal of Orthopaedic and Sports Physical Therapy, 14*(2), 90–99.

Brems, J. (1994). Rehabilitation following total shoulder arthroplasty. *Clinical Orthopaedics and Related Research, 307*, 70–85.

Browne, A. O., Hoffmeyer, P., Tanaka, S., & Morrey, B. F. (1990). Glenohumeral elevation studied in three dimensions. *The Journal of Bone and Joint Surgery. British Volume, 72*(5), 843–845.

Buchbinder, R., Youd, J. M., Green, S., Stein, A., Forbes, A., Harris, A., et al. (2007). Efficacy and cost-effectiveness of physiotherapy following glenohumeral joint distension for adhesive capsulitis: a randomized trial. *Arthritis and Rheumatism, 57*(6), 1027–1037.

Carette, S., Moffet, H., Tardif, J., Bessette, L., Morin, F., Frémont, P., et al. (2003). Intraarticular corticosteroids, supervised physiotherapy, or a combination of the two in the treatment of adhesive capsulitis of the shoulder: a placebo-controlled trial. *Arthritis and Rheumatism, 48*(3), 829–838.

Castellarin, G., Ricci, M., Vedovi, E., Vecchini, E., Sembenini, P., Marangon, A., et al. (2004). Manipulation and arthroscopy under general anesthesia and early rehabilitative treatment for frozen shoulders. *Archives of Physical Medicine and Rehabilitation, 85*(8), 1236–1240.

Cook, T. M., & Ludewig, P. M. (1996). The effect of head position on scapular orientation and muscle activity during shoulder elevation. *Journal of Occupational Rehabilitation, 6*(3), 147–158.

Cyriax, J. H. (1975) (6th revised ed.). *Textbook of orthopaedic medicine: diagnosis of soft tissue lesions* (Vol. 1) (pp. 61–98). Baltimore: Williams & Wilkins.

Dempsey, A. L., Mills, T., Karsch, R. M., & Branch, T. P. (2011). Maximizing total end range time is safe and effective for the conservative treatment of frozen shoulder patients. *American Journal of Physical Medicine & Rehabilitation/Association of Academic Physiatrists, 90*(9), 738–745. http://dx.doi.org/10.1097/PHM.0b013e318214ed0d.

Dias, R., Cutts, S., & Massoud, S. (2005). Frozen shoulder. *British Medical Journal, 331*(7530), 1453–1456.

Diercks, R. L., & Stevens, M. (2004). Gentle thawing of the frozen shoulder: a prospective study of supervised neglect versus intensive physical therapy in seventy-seven patients with frozen shoulder syndrome followed up for two years. *Journal of Shoulder and Elbow Surgery, 13*(5), 499–502.

Donatelli, R., Wilkes, J., Hall, W., & Cole, S. (2006). Frozen shoulder encapsulates therapy challenges. *Biomechanics, 2*, 31–46.

Doornberg, J. N., Ring, D., & Jupiter, J. B. (2006). Static progressive splinting for posttraumatic elbow stiffness. *Journal of Orthopaedic Trauma, 20*(6), 400–404.

Dudkiewicz, I., Oran, A., Salai, M., Palti, R., & Pritsch, M. (2004). Idiopathic adhesive capsulitis: long-term results of conservative treatment. *The Israel Medical Association Journal, 6*(9), 524–526.

Earley, D., & Shannon, M. (2006). The use of occupation-based treatment with a person who has shoulder adhesive capsulitis: a case report. *The American Journal of Occupational Therapy, 60*(4), 397–403.

Farrell, C. M., Sperling, J. W., & Cofield, R. H. (2005). Manipulation for frozen shoulder: long-term results. *Journal of Shoulder and Elbow Surgery, 14*(5), 480–484.

Geraets, J. J., Goossens, M. E., de Groot, I. J., de Bruijn, C. P., de Bie, R. A., Dinant, G. J., et al. (2005). Effectiveness of a graded exercise therapy program for patients with chronic shoulder complaints. *The Australian Journal of Physiotherapy, 51*(2), 87–94.

Green, S., Buchbinder, R., & Hetrick, S. E. (2003). Physiotherapy interventions for shoulder pain. *Cochrane Database of Systematic Reviews, 2*, CD004258.

Hand, C., Clipsham, K., Rees, J. L., & Carr, A. J. (2008). Long-term outcome of frozen shoulder. *Journal of Shoulder and Elbow Surgery, 17*(2), 231–236.

Hannafin, J. A., & Chiaia, T. A. (2000). Adhesive capsulitis: a treatment approach. *Clinical Orthopaedics and Related Research, 372*, 95–109.

Hay, E. M., Thomas, E., Paterson, S. M., Dziedzic, K., & Croft, P. R. (2003). A pragmatic randomised controlled trial of local corticosteroid injection and physiotherapy for the treatment of new episodes of unilateral shoulder pain in primary care. *Annals of the Rheumatic Diseases, 62*(5), 394–399.

Hébert, L. J., Moffet, H., McFadyen, B. J., & Dionne, C. E. (2002). Scapular behavior in shoulder impingement syndrome. *Archives of Physical Medicine and Rehabilitation, 83*(1), 60–69.

Ibrahim, M., Aaron, J., Robert, P., Kimona, I., Qasi, N., Bhaveen, H., et al. (2012). Treatment of adhesive capsulitis of the shoulder with a static progressive stretch device: a prospective, randomized study. *Journal of Long-term Effects of Medical Implants, 22*(4), 281–291.

Izumi, T., Aoki, M., Muraki, T., Hidaka, E., & Miyamoto, S. (2008). Stretching positions for the posterior capsule of the glenohumeral joint: strain measurement using cadaver specimens. *The American Journal of Sports Medicine, 36*(10), 2014–2022.

Izumi, T., Aoki, M., Tanaka, Y., Uchiyama, E., Suzuki, D., Miyamoto, S., et al. (2011). Stretching positions for the coracohumeral ligament: strain measurement during passive motion using fresh/frozen cadaver shoulders. *Sports Medicine, Arthroscopy, Rehabilitation, Therapy & Technology: SMARTT, 3*(1), 2. http://dx.doi.org/10.1186/1758-2555-3-2.

Jewell, D. V., Riddle, D. L., & Thacker, L. R. (2009). Interventions associated with an increased or decreased likelihood of pain reduction and improved function in patients with adhesive capsulitis: a retrospective cohort study. *Physical Therapy, 89*(5), 419–429.

Kelly, M. J., Shaffer, M. A., Kuhn, J. E., Michener, L. A., Seitz, A. L., Uhl, T. L., et al. (2013). Shoulder pain and mobility deficits: adhesive capsulitis. *The Journal of Orthopaedic and Sports Physical Therapy, 43*(5), A3–A31.

Kendall, F. P., McCreary, E. K., & Provance, P. G. (1993). *Muscles testing and function* (4th ed.). Baltimore: Williams and Wilkins.

Kibler, W. B. (1998). The role of the scapula in athletic shoulder function. *American Journal of Sports Medicine, 26*, 325–337.

Kivimäki, J., Pohjolainen, T., Malmivaara, A., Kannisto, M., Guillaume, J., Seitsalo, S., et al. (2007). Manipulation under anesthesia with home exercises versus home exercises alone in the treatment of frozen shoulder: a randomized, controlled trial with 125 patients. *Journal of Shoulder and Elbow Surgery, 16*(6), 722–726.

Konda, S., Yanai, T., & Sakurai, S. (2010). Scapular rotation to attain the peak shoulder external rotation in tennis serve. *Medicine and Science in Sports and Exercise, 42*(9), 1745–1753.

Laudner, K. G., Myers, J. B., Pasquale, M. R., Bradley, J. P., & Lephart, S. M. (2006). Scapular dysfunction in throwers with pathologic internal impingement. *The Journal of Orthopaedic and Sports Physical Therapy, 36*(7), 485–494.

Levine, W. N., Kashyap, C. P., Bak, S. F., Ahmad, C. S., Blaine, T. A., & Bigliani, L. U. (2007). Nonoperative management of idiopathic adhesive capsulitis. *Journal of Shoulder and Elbow Surgery, 16*(5), 569–573.

Light, K. E., Nuzik, S., Personius, W., & Barstrom, A. (1984). Low-load prolonged stretch vs. high-load brief stretch in treating knee contractures. *Physical Therapy, 64*(3), 330–333.

Lubiecki, M., & Carr, A. (2007). Frozen shoulder: past, present, and future. *Journal of Orthopaedic Surgery, 15*(1), 1–3.

Ludewig, P. M., & Reynolds, J. F. (2009). The association of scapular kinematics and glenohumeral joint pathologies. *The Journal of Orthopaedic and Sports Physical Therapy, 39*(2), 90–104.

Lundberg, B. J. (1970). Glycosaminoglycans of the normal and frozen shoulder-joint capsule. *Clinical Orthopaedics and Related Research, 69*, 279–284.

Mao, C. Y., Jaw, W. C., & Cheng, H. C. (1997). Frozen shoulder: correlation between the response to physical therapy and follow-up shoulder arthrography. *Archives of Physical Medicine and Rehabilitation, 78*(8), 857–859.

McClure, P., Blackburn, L., & Dusold, C. (1994). The use of splints in the treatment of joint stiffness: biologic rationale and an algorithm for making clinical decisions. *Physical Therapy, 74*, 1101Y7.

McClure, P. W., & Flowers, K. R. (1992). Treatment of limited shoulder motion using an elevation splint. *Physical Therapy, 72*(1), 57–62.

McClure, P. W., Michener, L. A., & Karduna, A. R. (2006). Shoulder function and 3-dimensional scapular kinematics in people with and without shoulder impingement syndrome. *Physical Therapy, 86*(8), 1075–1090.

McGahan, P. J., Patel, H., Dickinson, E., Leasure, J., & Montgomery, W. (2013). The effect of biceps adhesions on glenohumeral range of motion: a cadaveric study. *Journal of shoulder and elbow surgery/American Shoulder and Elbow Surgeons, 22*(5), 658–665. http://dx.doi.org/10.1016/j.jse.2012.07.003.

Michlovitz, S. L., Harris, B. A., & Watkins, M. P. (2004). Therapy interventions for improving joint range of motion: a systematic review. *Journal of Hand Therapy, 17*(2), 118–131.

Muraki, T., Aoki, M., Uchiyama, E., Takasaki, H., Murakami, G., & Miyamoto, S. (2007). A cadaveric study of strain on the subscapularis muscle. *Archives of Physical Medicine and Rehabilitation, 88*(7), 941–946.

Neumann, D. A. (2009). *Kinesiology of the musculoskeletal system* (2nd ed.). St. Louis: Mosby.

Neviaser, A. S., & Hannafin, J. A. (2010). Adhesive capsulitis: a review of current treatment. *The American Journal of Sports Medicine, 38*(11), 2346–2356.

Nordin, M., & Frankel, V. H. (2001). *Basic biomechanics of the musculoskeletal system* (3rd ed.). Philadelphia: Lippincott, Williams & Wilkins.

Norkin, C., & Levangie, P. K. (1992). *Joint structure and function: a comprehensive analysis* (2nd ed.). Philadelphia: F. A. Davis Publications.

Ozaki, J., Nakagawa, Y., Sakurai, G., & Tamai, S. (1989). Recalcitrant chronic adhesive capsulitis of the shoulder. Role of contracture of the coracohumeral ligament and rotator interval in pathogenesis and treatment. *The Journal of Bone and Joint Surgery. American Volume, 71*(10), 1511–1515.

Pearsall, A. W., & Speer, K. P. (1998). Frozen shoulder syndrome: diagnostic and treatment strategies in the primary care setting. *Medicine and Science in Sports and Exercise, 30*(4 Suppl), S33–S39.
Rizk, T. E., Christopher, R. P., Pinals, R. S., Higgins, A. C., & Frix, R. (1983). Adhesive capsulitis (frozen shoulder): a new approach to its management. *Archives of Physical Medicine and Rehabilitation, 64*(1), 29–33.
Smidt, N., de Vet, H. C., Bouter, L. M., Dekker, J., Arendzen, J. H., de Bie, R. A., et al. (2005). Effectiveness of exercise therapy: a best-evidence summary of systematic reviews. *The Australian Journal of Physiotherapy, 51*(2), 71–85.
Solem-Bertoft, E., Thuomas, K. A., & Westerberg, C. E. (1993). The influence of scapula retraction and protraction on the width of the subacromial space: an MRI study. *Clinical Orthopaedics and Related Research, 296*, 99–103.
Soren, A., & Fetto, J. F. (1996). Contracture of the shoulder joint. *Archives of Orthopaedic and Trauma Surgery, 115*(5), 270–272.
Su, K. P., Johnson, M. P., Gracely, E. J., & Karduna, A. R. (2004). Scapular rotation in swimmers with and without impingement syndrome: practice effects. *Medicine and Science in Sports and Exercise, 36*(7), 1117–1123.
Turkel, S. J., Panio, M. W., Marshall, J. L., & Girgis, F. G. (1981). Stabilizing mechanisms preventing anterior dislocation of the glenohumeral joint. *The Journal of Bone and Joint Surgery. American Volume, 63*(8), 1208–1217.
Tyler, T. F., Roy, T., Nicholas, S. J., & Gleim, G. W. (1999). Reliability and validity of a new method of measuring posterior shoulder tightness. *The Journal of Orthopaedic and Sports Physical Therapy, 29*(5), 262–269.
Uhthoff, H., & Boileau, P. (2007). Primary frozen shoulder: a global capsular stiffness versus localized contracture. *Clinical Orthopaedics and Related Research, 456*, 79–84.
Ulrich, S. D., Bonutti, P. M., Seyler, T. M., Marker, D. R., Morrey, B. F., & Mont, M. A. (2010). Restoring range of motion via stress relaxation and static progressive stretch in posttraumatic elbow contractures. *Journal of Shoulder and Elbow Surgery, 19*(2), 196–201.
Vermeulen, H. M., Obermann, W. R., Burger, B. J., Kok, G. J., Rozing, P. M., & van Den Ende, C. H. (2000). End-range mobilization techniques in adhesive capsulitis of the shoulder joint: a multiple-subject case report. *Physical Therapy, 80*(12), 1204–1213.
Vermeulen, H. M., Rozing, P. M., Obermann, W. R., le Cessie, S., & Vliet Vlieland, T. P. (2006). Comparison of high-grade and low-grade mobilization techniques in the management of adhesive capsulitis of the shoulder: randomized controlled trial. *Physical Therapy, 86*(3), 355–368.
Vermeulen, H. M., Stokdijk, M., Eilers, P. H., Meskers, C. G., Rozing, P. M., & Vliet Vlieland, T. P. (2002). Measurement of three dimensional shoulder movement patterns with an electromagnetic tracking device in patients with a frozen shoulder. *Annals of the Rheumatic Diseases, 61*(2), 115–120.
Warren, C. G., Lehmann, J. F., & Koblanski, J. N. (1971). Elongation of rat tail tendon: effect of load and temperature. *Archives of Physical Medicine and Rehabilitation, 52*(10), 465–474.
Wong, P. L. K., & Tan, H. C. A. (2010). A review on frozen shoulder. *Singapore Medical Journal, 51*, 694–697.
Yang, J. L., Chang, C. W., Chen, S. Y., Wang, S. F., & Lin, J. J. (2007). Mobilization techniques in subjects with frozen shoulder syndrome: randomized multiple-treatment trial. *Physical Therapy, 87*(10), 1307–1315.
Yang, J., Jan, M.-H., Chang, C., & Lin, J. (2012). Effectiveness of the end-range mobilization and scapular mobilization approach in a subgroup of subjects with frozen shoulder syndrome: a randomized control trial. *Manual Therapy, 17*(1), 47–52.
Zuckerman, J., & Rokito, S. (2011). Definition and classification of frozen shoulder: a consensus approach. *Journal of Shoulder and Elbow Surgery, 20*, 322–335.

View publication stats